

Caso 1/2007

Reliable In-Stent Lumen Visualization With Dual Source CT Coronary Angiography

By Annick C. Weustink, MD, and Nico R. Mollet, MD, PhD,
Departments of Radiology and Cardiology, Erasmus Medical Center, Rotterdam, the Netherlands

HISTÓRIA

A 58-year-old man with a history of hypertension and hypercholesterolemia was admitted to the hospital with symptoms of suspected stable angina pectoris.

The patient was referred to conventional coronary angiography after a positive exercise-ECG test. Conventional angiography showed significant stenoses at the level of the proximal right coronary artery (RCA) and the proximal left anterior descending coronary artery (LAD).

Percutaneous intervention was undertaken and one bare-metal stent in the RCA and two overlapping bare-metal stents in the LAD were successfully implanted. The patient was referred to follow-up CT coronary angiography after 18 months.

DIAGNÓSTICO

The patient was scanned on a Dual Source CT (DSCT) scanner. Nitroglycerine was administered prior to the CT scan; however, the patient did not receive prescan beta-blockers. The patient had a heart rate of 76 beats/minute during the CT scan.

DSCT coronary angiography was able to reliably rule out the presence of in-stent restenosis in both the RCA and LAD stents.

COMENTÁRIOS

The SOMATOM® Definition CT scanner uses two X-ray sources and two detectors at the same time. This is one of the important features for cardiac CT scanning. It allows scanning of the heart with a heart rate-independent temporal resolution of 83 ms. As a result, high-quality images of the rapidly-moving coronary arteries are obtained even with higher heart rates.

Moreover, the adaptive pitch and use of prospective ECG-tube modulation allows significant reduction of the radiation exposure during cardiac CT scanning, especially with higher heart rates.

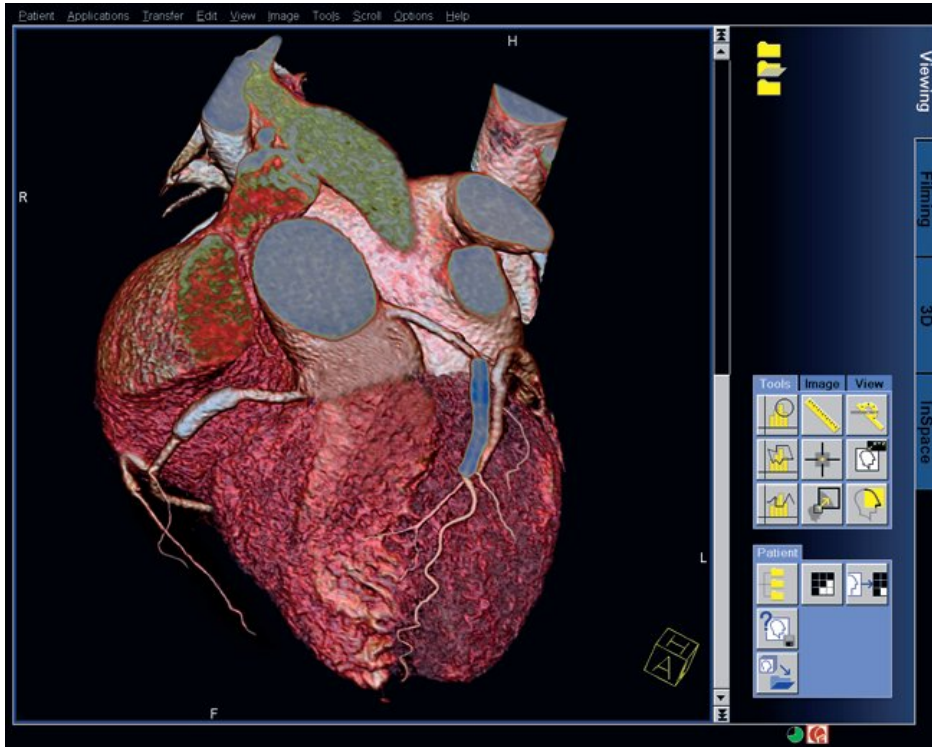
This example shows clear delineation of the stents with excellent visualization of the in-stent lumen without the need for pre-scan beta-blockers in a patient with a heart rate of 76 beats/minute.

It demonstrates the potential of DSCT coronary angiography to rule out the presence of in-stent restenosis in follow-up patients after percutaneous intervention procedures.

PROTOCOLO DO EXAME

Scanner	SOMATOM Definition
Scan area	Heart
Scan length	103 mm
Scan time	7,3 sec
Scan direction	Caudo-cranial
Heart rate	76 bpm
kV	120 kV
mAs / Rot	400 mAs/rot
Rotation time	0.33 sec
Temporal resolution HR independent 83 msec	HR independent 83 msec
Slice collimation	0.6 mm
Spatial resolution	0.33 mm
Pitch	0.32
Reconstructed slice thickness	0.75 mm
Increment	0.4 mm
Prospective ECG-tube modulation	On, window: 30–60%

CTDI vol	45,31 mGy
Kernel	B46f
Contrast material volume	90 ml
Flow rate	5,5 ml/s
Bolus tracking	on



1 - Volume Rendered CT image showing the stents in the proximal-to-mid LAD and the mid part of the RCA.



2 e 3 - Curved multiplanar CT images showing excellent visualization of the in-stent lumen of both the RCA (Fig. 2) and LAD (Fig. 3) stents, thereby reliably ruling out the presence of in-stent restenosis.